

Efficacy of HBOT in Central Retinal Artery Occlusion : Visual Outcome

Manoj Gupta

Abstract

Background: Visual loss is a major symptom in Central Retinal Artery Occlusion, while limited vision field has been described in Branched Retinal Artery Occlusion. Despite great developments in diagnostic, surgical and medical ophthalmology fields within recent years, retinal artery occlusion still remains a disease without approved therapy. Retinal cells consumed the highest oxygen consumption in organs, which makes the retina extremely susceptible to ischemia. **Aim and Objective:** The aim and objective of this prospective study was to look for effect of hyperbaric oxygen therapy and to evaluate and establish a possible marker for retinal damage. **Study Design:** Prospective case control study. **Place of Study:** The study was carried out at the Prana Hyper Baric Oxygen Therapy Centre, located in the Northern parts of Mumbai, in India. **Material and Method:** Total 62 patients with central retinal artery occlusion were included which were referred to our Prana hyperbaric center Mumbai over a period of three years. The HBO therapy protocol included 90 minutes oxygen breathing at 2 ata twice daily for 3 days and then followed by 1 OD for 4 days. **Results and Discussion:** The best corrected visual acuity [log MAR] after hyperbaric oxygen therapy compared with baseline showed a significant mean improvement of 0.612 ± 0.64 from 2.16 ± 0.48 to 1.58 ± 0.89 [$p < 0.0001$]. Similarly BCVA [log MAR] after HBOT in patients with cherry red spot compared with base line showed a mean improvement of 0.453 ± 0.358 from 2.24 ± 0.32 to 1.87 ± 0.54 [$p < 0.0001$] also showed a significant finding in non cherry red spot cases where BCVA after HBOT compared with base line showed a mean improvement of 0.78 ± 0.498 from 1.96 ± 0.68 to 1.21 ± 0.71 [$p < 0.0001$]. **Conclusion:** From clinical perspective hyperbaric oxygen therapy is an effective treatment for central retinal artery occlusion cases, it also concludes that the cherry red spot as marker of retinal infarction and as long as it is not being developed the prognosis appears to be good.

Keywords: Central Retinal Artery Occlusion; Hyperbaric Oxygen therapy; Cherry Red Spot.

How to cite this article:

Manoj Gupta. Efficacy of HBOT in Central Retinal Artery Occlusion: Visual Outcome. Ophthalmol Allied Sci. 2019;5(2):180-185.

Introduction

Von Graefe 1859 was the first to describe central retinal artery occlusion due to embolism, since then it has been known as a clinical entity [1]. Later in 1864 it was described on ophthalmoscopy by Schweigger [2]. From Internal carotid artery, ophthalmic artery originates and central retinal artery is a small but important branch of ophthalmic artery. Inner layer of retina gets its blood supply from central retinal

artery and its branches [3]. Thrombosis, arteritis, embolus, vasospasm are the main aetiology of retinal artery occlusions [4]. The very consequences clinically are dramatic and treatment delay may cause blindness, retinal artery occlusion is much more common in hypertensive arteriosclerosis patients and also occasionally in patients with endocarditis [5,6]. Major symptom in central retinal artery occlusion is loss of vision, whereas limited vision field seen in branch retinal artery occlusion.

The ophthalmic artery originates from the internal carotid artery, and the central retinal artery is a small important branch of the ophthalmic artery. The blood supply of the inner layer of the retina comes from the Central Retinal Artery and its branches; occlusion of the branch leads to a branch retinal artery occlusion [3]. The etiology of Retinal Artery Occlusion includes thrombosis, embolus, arteritis, vasospasm [4]. Clinically, the consequences of this vascular accident are dramatic, and delayed treatment may lead to

Author Affiliation: Director, Prana Hyperbaric Oxygen Therapy Center, Borivali West, Mumbai, Maharashtra 400092, India.

Corresponding Author: Manoj Gupta. Sailee Hospital & Diagnostic Center, Prathamesh Horizon, New MHB Colony, New Link Road, Borivali West, Mumbai, Maharashtra 400091, India.

E-mail: drmanojgupta222@gmail.com

Received on 23.05.2019, **Accepted on** 20.06.2019

blindness; Retinal Artery Occlusion is more common in hypertensive arteriosclerosis patients and occurs occasionally patients with endocarditis [5,6]. Visual loss is a major symptom in Central Retinal Artery Occlusion, while limited vision field has been described in Branched Retinal Artery Occlusion. Despite great developments in diagnostic, surgical and medical ophthalmology fields within recent years, retinal artery occlusion still remains a disease without approved therapy. Retinal cells consumed the highest oxygen consumption in organs, which makes the retina extremely susceptible to ischemia [7]. The inner retinal layers are normally supported by retinal circulation and typically lose viability, leading to vision loss.

In Animal studies it is clearly shown that total retinal ischemia can be entirely reversed provided the retina is reoxygenized within 97 minutes of onset of the symptoms [8]. In comparison to the animal studies in humans there is no clear timeline seen until irreversible anoxic retinal damage occurs. Few authors suggest elapsed time of around 6–6.5 hours [9] but this may be due to the large variability between patients, types of occlusion, and residual perfusion, such time frame is not considered to be reliable and hence different biologically based marker is required.

Central retinal artery occlusion an emergency eye situation that should be suspected in patient who presents with unilateral sudden painless vision loss, such patients usually had vision loss in the range of finger counting to light perception. Patients presenting with no light perception in the affected eye might had occluded the ophthalmic artery close to where it enters the eye which causes permanent and debilitating vision loss.

The proposed role for hyperbaric oxygen in Central Retinal Artery Occlusion is to increase the oxygen delivery to the ischemic tissue until spontaneous or assisted reperfusion occurs. Hyperbaric oxygen therapy includes the inhalation of 100% oxygen at pressures exceeding 1 atmosphere absolute (ATA) to enhance the amount of oxygen dissolved in the body tissues. During Hyperbaric oxygen therapy treatment arterial O₂ tension typically exceeds 2,000 mm Hg [10]. The aim and objective of this prospective study was to look for effect of hyperbaric oxygen therapy and to evaluate and establish a possible marker for retinal damage which included cases of non arteritic central retinal artery occlusion patients.

Materials and Methods

Study Setting

The study was carried out at the Prana Hyper

Baric Oxygen Therapy Centre, which is owned by the Investigator and located in the Northern parts of Mumbai, in India. The center has one Sechrist Monoplace hyperbaric chamber and a TCOM machine with 3 electrodes. The oxygen gas supply is from oxygen cylinders of 7000 liters' capacity each. The center has all the requisite certifications and registrations as required by the local authority in Mumbai. Study was conducted over a period of 3 years and patient with Central retinal artery occlusion referred to the Hyperbaric Unit at Prana HBO center. Center took care in a specialized form and provided care to patients with central retinal artery occlusive conditions and was responsible for caring for all patients. Written informed consent was obtained from the patient and patient's relative.

Study Design

Study carried out was prospective case control study.

Study Population

In our study total 62 patients with central retinal artery occlusion were included which were referred to our Prana hyperbaric center Mumbai over a period of three years. Furthermore all the patients were screened for eligibility to be included in the study

Inclusion Criteria

Patients referred to Prana Hyperbaric center, with age more than 18 years non arteritic central retinal artery occlusion with symptoms not more than 20 hours and best corrected visual acuity worse than 0.5 logarithm of minimum angle of resolution [log MAR] were included in the study.

Exclusion Criteria

All of the following patients who discontinued therapy during the treatment, with excessive best corrected visual acuity more than 0.5 log Mar, arteritic central retinal artery occlusion, patent cilio retinal artery, other final diagnosis and branch retinal artery occlusion cases were excluded from the study.

Ethics Review

This study was performed within the scope of international ethical guidelines and legislation. Ethics review and approval was provided by Stellenbosch University (number: U16/06/015) and the ethics committee of the Hyperbaric Society in India.

Procedure

In our study the patients with suspected central retinal artery occlusion were included and treated with hyperbaric oxygen therapy for retinal artery occlusion. The HBO therapy protocol included 90 minutes oxygen breathing at 2 ata twice daily for 3 days and then followed by 1 OD for 4 days. During the course of recruitment of the patients for the study detailed neurologic and cardiologic examinations were done while hospitalization to establish the cause of occlusion in such cases. Echocardiography, duplex ultrasound of the carotid arteries was also performed as a part of the investigation during inclusion of the patients. All the safety precautions of hyperbaric oxygen therapy in regards with adverse reactions were meticulously monitored and analyzed.

Statistical Analysis

Numerical Data Present in graphically and descriptive statistics like mean, standard deviation, confidence interval etc. done on numeric variables. A large sample t-test was performed on numerical data. Correlation analysis to measure the relation between variable which was performed on change in BCVA and Treatment time from symptoms to treatment and chi square test was performed to check the significance. Regression analysis was used. All statistical analysis was done by using the Statistical package for the Social Science [SPSS] V.19 software.

Results

In our prospective case control study total 62 patients were enrolled who fulfilled the inclusion criterion and were included for the final analysis of the study. 10 cases were excluded from the study due to the time delay of more than 20 hours for treatment but were separately analyzed for best

corrected visual acuity pointed and highlighted in Figure 3 of the study. In our study mean age of the patients was 65.3 ± 11.8 years and out of the total 62 cases 44 patients were males (Table 1). The most prevalent chronic medical conditions were hypertension followed by hypercholesterolemia and active smoking with 38, 28 and 21 cases respectively involved. Out of that 22 cases were on treatment with statins prior to the central retinal artery occlusion event. In our study the mean time delay from onset of symptoms to actual starting of the treatment for CRAO event was 7.3 ± 4.1 hours. The average number of hyperbaric oxygen therapy sessions was 3.9 ± 1.4 . In our study right eye was affected in 27 cases whereas left eye was involved in 35 cases. The intra ocular pressure was 13.4 ± 3.9 mmHg. 40 patients presented with cherry red spot in the study. The best corrected visual acuity [log MAR] after hyperbaric oxygen therapy compared with baseline showed a significant mean improvement of 0.612 ± 0.64 from 2.16 ± 0.48 to 1.58 ± 0.89 [$p < 0.0001$]. similarly BCVA [log MAR] after HBOT in patients with cherry red spot compared with base line showed a mean improvement of 0.453 ± 0.358 from 2.24 ± 0.32 to 1.87 ± 0.54 [$p < 0.0001$] also showed a significant finding in non cherry red spot cases where BCVA after HBOT compared with base line showed a mean improvement of 0.78 ± 0.498 from 1.96 ± 0.68 to 1.21 ± 0.71 [$p < 0.0001$]. (Table 2) (Fig. 3). The visual outcome of the patients with delayed presentation for treatment i.e. more than 20 hours from onset of symptoms is being displayed in Table 3. It was found that the presence of plaque or boxcarrying during fundus examination had no effect on visual outcome in the study. In the present study no patients had any episodes of major adverse events, few minor events were observed in 2 patients experienced with otalgia without barotruma signs, none of the cases need to be intervened by any procedures to continue HBOT.

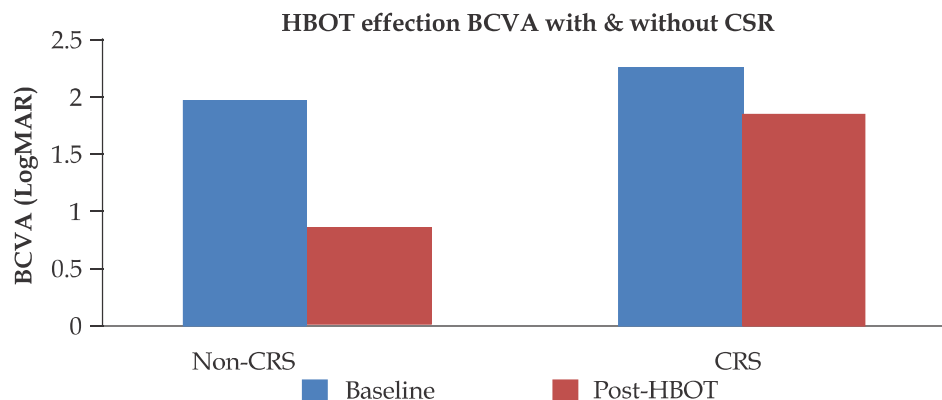


Fig. 1: Hyperbaric oxygen therapy effects on BCVA in patients with and without cherry red spots.

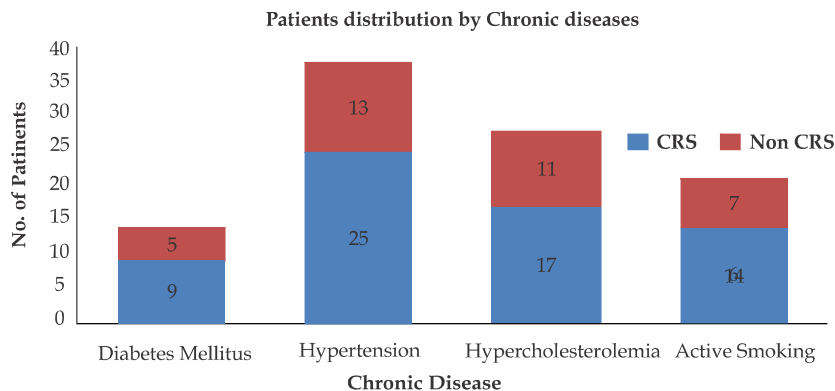


Fig. 2: Patient distributions by chronic diseases

Table 1: Patient's baseline characteristics

Characteristics	HBOT	CRS	Non - CRS	Significance
Male	44	29	15	
Female	18	11	07	
Age	65.3 ± 11.8	66.14 ± 12.2	64.2 ± 11.3	0.00315
<i>Chronic Medical Condition:</i>				
Diabetes Mellitus	14	09	05	
Hypertension	38	25	13	
Hypercholesterolemia	28	17	11	
Active Smoking	21	14	07	
<i>Chronic Medications:</i>				
Statins	22	14	08	
<i>Involved Eye:</i>				
Right	27	18	09	
Left	35	22	13	
Time from symptoms to treatment	7.3 ± 4.1 (1-20)	7.9 ± 4.3 (2-19)	6.9 ± 3.9 (1-20)	0.0000211
Intraocular Pressure	13.4 ± 3.9	12.9 ± 3.4	14.1 ± 4.5	0.00001
<i>Fundus Finding:</i>				
Plaque	14	08	06	
CRS	40	-	-	
Boxcarring	12	07	05	
<i>Number of HBOT sessions:</i>				
Median = 3.9	3.9 ± 1.4	4 ± 1.1	3.8 ± 1	0.0021

Table 2: Analysis of best corrected visual acuity

Outcomes	All Patients (n= 62)	CRS (n= 40)	Non - CRS (n= 22)	Significance
Baseline Log MAR	2.16 ± 0.48	2.24 ± 0.32	1.96 ± 0.68	0.00002
Discharge log MAR	1.58 ± 0.89	1.87 ± 0.54	1.21 ± 0.71	0.0001
Change in log MAR	0.612 ± 0.64	0.453 ± 0.358	0.78 ± 0.498	0.0001
Clinical significant usual improvement ≥0.3 log MAR	42	23	19	0.00001
Log MAR ≤ 1	16	3	13	0.0001

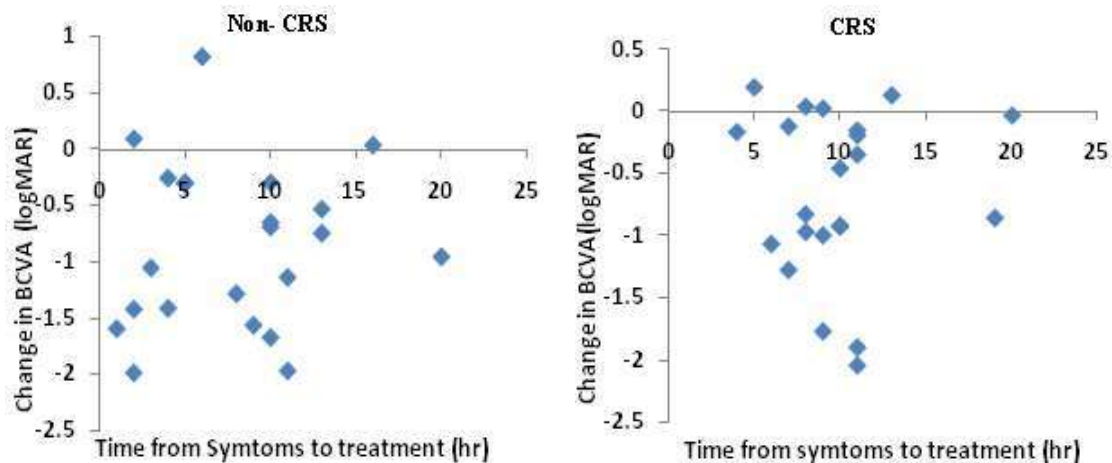
Discussion

In our present study we evaluated therapeutic effect of hyperbaric oxygen in patients suffering

from non arteritic central retinal artery occlusion. There are various studies, case reports and cohort studies that had shown the very efficacy of using hyperbaric oxygen in patients with retinal artery occlusion in various time frames [11-15]. But

Table 3: Analysis of BCVA for patients with time delay of over 20 hours

Outcomes	All Patients (n= 10)	CRS (n= 07)	Non - CRS (n= 03)	Significance
Baseline Log MAR	2.01 ± 0.52	2.04 ± 0.42	1.98 ± 0.51	0.8612
Discharge log MAR	1.84 ± 0.89	2.16 ± 0.55	1.65 ± 0.68	0.061
Change in log MAR	0.421 ± 0.694	0.124 ± 0.242	0.684 ± 0.389	0.135
Clinical significant usual improvement ≥ 0.3 log MAR	4	1	3	0.123
Log MAR ≤ 1	5	2	3	0.315

**Fig. 3:** Change in BCVA post HBOT and time delay to treatment as a factor.

the point to highlight was that many cases were from branched retinal artery occlusion, arteritic retinal occlusion or central retinal artery occlusion. Near related causes of retinal arterial occlusive diseases includes atherosclerosis related thrombus, embolism, vasospasm and giant cell arteritis. Central retinal artery occlusion with significant loss of vision is considered as ophthalmic emergency, treatment should be aimed at prompt supply of oxygen to ischemic retina at a partial pressure which is sufficient to maintain viability during medically assisted or spontaneous restoration of central retinal artery blood flow is established. In Animal model research of retinal artery injury have shown a reduction in apoptosis from 58% of cell loss to 30% in animals treated with hyperbaric oxygen [16].

The retinal tissue undergoes a period of ischemia when retinal arterial flow is interrupted, blood flow is usually re-established via re-canalization but if hypoxia and ischemia resulted in cell death and necrosis in the inner layers of the retina, vision may not return even if the blood flow is re-established. Ischemic Penumbra is a term used when tissue that is ischemic yet capable of recovery within a certain time frame [17]. In the study reported by Stone et.

al. two patients with CRAo of more than six hours duration were treated with intermittent carbogen i.e. 95% oxygen and 5% CO₂, retrobulbar anesthesia and anterior chamber paracentesis. In his study the first patient vision improved from hand motion to 20/20 due to the above mentioned therapy, wherein the carbogen was being administered for every 10 minutes every hour, on the contrary the second patient had improvement from finger counting to 20/25 where the carbogen was administered 10 minutes every hour for 48 hours [18].

In the study reported by Hertoz *et. al.* 17 patients with central retinal artery occlusion were treated with HBOT, he divided the patient into four groups based on the time to onset of treatment and highlighted the HBO₂ seemed useful in preserving visual function when the therapy was given within eight hours from the onset of visual impairment [19].

In the present prospective case control study we evaluated the therapeutic effect of hyperbaric oxygen in patients referred to our Prana hyperbaric center suffering from acute central retinal artery occlusion, the important predictor in the study was no cherry red spot at fundus examination, the improvement in patient without cherry red spot

was significant that is 19 patients gaining clinical improvement [log MAR change ≥ 0.3] and 13 patients gaining best corrected visual acuity ≤ 1 log MAR making the basis to this finding it was concluded that cherry red spot can serve as marker for irreversible anoxic retinal damage to be used for patients for hyperbaric oxygen therapy, as well it can be used in future studies designed to evaluate different interventions aiming to reverse retinal ischemia. However, in our study there was no control group, as such it is not possible to have due to ethical reasons also central retinal artery occlusion is approved indication for hyperbaric oxygen therapy, since the visual improvement occurred quite dramatic within minutes after the target treatment pressure was obtained when the patient was in chamber as well then there was not any improvement until hyperbaric oxygen therapy session started, it can be concluded that the improvement in vision is related to increased retinal oxygenation with hyper baric oxygen.

Conclusion

From clinical perspective hyperbaric oxygen therapy is an effective treatment for central retinal artery occlusion cases, it also concludes that the cherry red spot as marker of retinal infarction and as long as it is not being developed the prognosis appears to be good. Hyperbaric oxygen therapy is a safe and non invasive intervention that should be considered with priority in central retinal artery occlusion patients. The fundus findings should be considered as an important marker to look for the outcome of treatment success.

Conflict of Interest: The author declares no conflict of interest for this study.

References

1. Von Graefe A. Über Embolie der Arteria centralis retinaeals Ursache plötzlicher Erblindung. Albrecht v Graefes Arch Ophthalmol. 1859;5:13685.
2. Schweigger K. Vorlesungen über den Gebrauch des Augenspiegels. Berlin: Mylius'sche Verlags Buchhandlung; 1864.
3. Dattilo M, Biousse V, Newman NJ. Update on the Management of Central Retinal Artery Occlusion. Neurologic Clinics. 2017;35(1):83. <https://doi.org/10.1016/j.ncl.2016.08.013> PMID: 27886897.
4. Hayreh SS, Podhajsky PA, Zimmerman MB. Retinal Artery Occlusion: Associated Systemic and Ophthalmic Abnormalities. Ophthalmology. 2009;116(10):1928. <https://doi.org/10.1016/j.optha.2009.03.006> PMID: 19577305.
5. Lu CW, Wang J, Zhou DD, *et al.* Central retinal artery occlusion associated with persistent truncus arteriosus and single atrium: a case report. BMC Ophthalmology. 2015;15(1):137.
6. Hong JH, Sohn SI, Kwak J, *et al.* Retinal artery occlusion and associated recurrent vascular risk with underlying etiologies. Plos One. 2017; 12(6):e0177663. <https://doi.org/10.1371/journal.pone.0177663> PMID: 28570629.
7. Hertzog LM, Meyer GW, Carson S, *et al.* Central retinal artery occlusion treated with hyperbaric oxygen. 1992.
8. Hayreh SS, Zimmerman MB, Kimura A, *et al.* Central retinal artery occlusion. Retinal survival time. Exp Eye Res. 2004;78(3):723–36.
9. Landa E, Rehany U, Rumelt S. Visual functions following recovery from non-arteritic central retinal artery occlusion. Ophthalmic Surg Lasers Imaging. 2004;35(2):103–08.
10. Fosen KM, Thom SR. Hyperbaric oxygen, vasculogenic stem cells, and wound healing. Antioxid Redox Signal. 2014;21(11):1634–1647.
11. Weiss JN. Hyperbaric oxygen treatment of nonacute central retinal artery occlusion. Undersea Hyperb Med. 2009;36(6):401–05.
12. Weinberger AW, Siekmann UP, Wolf S, Rossaint R, Kirchhof B, Schrage NF. [Treatment of Acute Central Retinal Artery Occlusion (CRAO) by Hyperbaric Oxygenation Therapy (HBO)-Pilot study with 21 patients]. Klinische Monatsblätter für Augenheilkunde. 2002;219(10):728–34. German.
13. Beiran I, Reissman P, Scharf J, Nahum Z, Miller B. Hyperbaric oxygenation combined with nifedipine treatment for recent-onset retinal artery occlusion. Eur J Ophthalmol. 1993;3(2):89–94.
14. Aisenbrey S, Krott R, Heller R, Krauss D, Rossler G, Heimann K. [Hyperbaric oxygen therapy in retinal artery occlusion]. Der Ophthalmologe: Zeitschrift der Deutschen Ophthalmologischen Gesellschaft. 2000;97(7):461–67. German.
15. Murphy-Lavoie H, Butler F, Hagan C. Central retinal artery occlusion treated with oxygen: a literature review and treatment algorithm. Undersea Hyperb Med. 2012;39(5):943–53.
16. Gaydar V, Ezraichi D, Dratviman-Storobinsky O *et al.* Invest Ophthalmol Vis Sci. 2011;52:7514–22.
17. Mangat HS. Retinal artery occlusion. Surv Ophthalmol. 1995;40:145–156.
18. Stone R, Zink H, Klingele T, Burde R. Visual recovery after central retinal artery occlusion: Two Cases. Ann Ophthalmol. 1977;9:445–50.
19. Hertzog LM, Meyer GW, Carson S, *et al.* Central retinal artery occlusion treated with hyperbaric oxygen. J Hyperbaric Medicine. 1992;7:33–42.